



Nonsyndromic familial Oligodontia in a 13 year old male: A case report

Richa Wadhawan^{1*}, Kaushal Luthra², Sushma Mishra³

¹ Reader, Department of Oral Medicine, Diagnosis & Radiology, Institute of Dental Education & Advance studies, Gwalior, Madhya Pradesh, India

² Principal, Professor & Head, Department of Periodontics, Institute of Dental Education & Advance studies, Gwalior, Madhya Pradesh, India

³ Junior Resident, Shyam Shah Medical college, Rewa, Madhya Pradesh, India

DOI: <https://doi.org/10.33545/26648733.2019.v1.i2a.12>

Abstract

The most common oral developmental anomaly is dental agenesis which can be either in the form of Anodontia, Oligodontia, or Hyperdontia. This can occur either as an isolated finding or as part of a syndrome. Nonsyndromic Oligodontia is rare. Early intervention and prompt management improves quality of life. Here, we report a case of a 13-year-old male child with non-Syndromic Oligodontia without any association with specific systemic disease who allegedly had complete set of primary teeth but failed to develop complete permanent dentition.

Keywords: dental agenesis, Anodontia, Hypodontia, Oligodontia, developmental anomaly

Introduction

Congenital absence of more than six teeth in primary, permanent or both dentitions excluding wisdom teeth is Oligodontia [1]. It is a rare genetic disorder which can occur as an isolated entity or in association with syndrome. Developmental disturbances in the initiation and proliferation stages of tooth formation leads to anomalies of tooth number, such as tooth agenesis or supernumerary teeth [2]. Higher frequencies of oligodontia in females have been reported. Considerations must be taken into account of not only the number of missing teeth, but also the type of missing teeth. In permanent dentition the teeth most often absent are maxillary and mandibular premolars and maxillary lateral incisors whereas canines, first and second molars and maxillary central incisors are rarely absent [3]. Oligodontia can be found or as part of a malformative syndrome, such as ectodermal dysplasia, BlochSulzberger, Down, Robinson's, Gorlin's, hypertrichosis, orofaciadigital & chondroectodermal dysplasia, Rieger's, and Nance-Horan syndrome as an isolated nonsyndromic trait [4]. Additionally, oligodontia may result in such anomalies as delayed tooth formation, taurodontism, and, eventually, deciduous retained teeth, atrophy of the alveolar ridge, and aberrations of teeth dimension and shape [5]. Non syndromic oligodontia are found to be associated with mutation in MSX1 and PAX9 genes. Environmental causes, intrauterine diseases, infectious diseases, drug use, radiotherapy application, trauma, viral disease during pregnancy, genetic predisposition, metabolic imbalances, developmental abnormalities and nutritional imbalances are some other etiological factors in non-syndromic oligodontia [6].

Case report

A 13-year-old male patient reported to the Department of Oral Medicine, Diagnosis & Radiology, Institute of Dental Education and Advance Studies, Gwalior, Madhya Pradesh reported to our dental college with chief complaint of missing teeth in upper and lower jaw region since 6 years. Patient gives history of uneruption

of permanent successor after exfoliation of deciduous predecessor. Family history reveals congenitally missing few permanent and deciduous teeth of his maternal uncle and cousin. Extra oral examination revealed no facial asymmetry (Figure 1). Intraoral clinical examination revealed few missing teeth in maxillary & mandibular arches (Figure 2).

Teeth present, 17, 16, 55, 24, 25, 26, 27, 47, 46, 45, 44, 43, 83, 33, 34, 75, 36, 37

Patient has grade III mobility in relation to mandibular right deciduous canine. Panoramic radiograph was advised. It reveals permanent dental germs were not developed of few teeth in both maxillary and mandibular arches (Figure 3).

Missing teeth were, 15, 14, 1312, 11, 2122, 2328, 42, 41, 31, 32 Hence diagnosis of oligodontia was given as twelve teeth were congenitally missing excluding left maxillary third molar. Patient was referred to department of pedodontics and preventive dentistry. Patient underwent extraction in relation to 83. Alginate impression was taken for maxillary as well as mandibular arches. Casts were poured. Removable partial dentures were fabricated for both jaws for replacement of missing dentition.

Discussion

Oligodontia is a hereditary disorder. There is variable expression and complete penetrance and the mode of transmission is autosomal dominant inheritance. There is role of mutation in multiple genes which in turn leads to disruption of the mechanisms controlling the dentition pattern or the progression of dental development [7]. It is caused by mutations of MSX1 and PAX9 genes and mutation in WNT10A gene is responsible for syndromes as well as of a substantial number of non-syndromic oligodontia. Mutations in the gene coding for the AXIN2 protein, a regulator of the Wnt signalling pathway, are implicated in the association between oligodontia and a predisposition to colorectal cancer [8]. Oligodontia may also exist in association with cleft lip and/or palate in other syndromes. Mutation in IRF6

gene is responsible for association of oligodontia with Van der Woude syndrome [9]. Oligodontia may be associated with other symptoms affecting ectodermal structures such as skin, nails, hair, sweat glands, saliva glands, mammary glands and the nasolacrimal duct, and it may be clinically associated with ectodermal dysplasia, a huge group of rare diseases. In that case, many genes of the Nf-kappab and Wnt pathways are implicated [10]. Some of them, such as EDA and EDARADD are also responsible for isolated oligodontia, without associated manifestations. It can also be associated with other syndromes, such as Down syndrome [11]. Oligodontia results in poor orofacial appearance, functional problems and malocclusion. An interdisciplinary and usually staged treatment approach is needed for complete rehabilitation which involves pediatric dentist, orthodontist, prosthodontist, oral surgeon and psychologist [12]. Factors which should be taken into account for the prosthetic treatment planning are patient's age, expectation of treatment of the patient, psychosocial aspects, the condition of retained primary teeth, the number of missing teeth & type of malocclusion [13]. Treatment options include fixed or removable prosthesis, which may or may not be implant retained. A scrupulous knowledge of craniofacial growth and development is required for management of such patient [14]. Periodic monitoring and long-term follow-up is necessary for the modification and/or replacement of the prosthesis due to growth of craniofacial and jaw bones [15]. According to the patient need, treatment might commence early. Removable prosthesis could be proposed for toddlers. These prostheses can be renewed as the child grows [16]. In growing patients with oligodontia, definitive therapies, such as surgical positioning of implants, could determine a risk of developmental deficiencies of local bone ridge & thus should be postpone to the end of dental growth [17]. If only anterior teeth are missing in hypodontia or oligodontia, a flexible system allowing slight movement of a bridge can be created by bonding an acrylic tooth to the supporting structure by means of three orthodontic wires. When growth is stabilized, osseointegrated endosseous implants may be an alternative to support, stabilize, and retain the prosthesis [18]. The patient's speech, articulation and masticatory function advanced greatly. Generally, the prosthodontic challenges are lack of uniformity of the occlusal plane, supereruption, loss of vertical dimension, and bone morphology in edentulous areas may cause. In cases of compromised alveolar bone level and jaw associations, bone augmentation and orthognathic surgery may be necessary. These treatments modalities are arduous. Over denture treatment choice is simple as well as reversible [19]. This treatment option can provide means for restoring ideal occlusion, increasing the vertical dimension and improving the self-reliance of those patients. The use of overdenture covering the alveolar arch and partly supported by natural teeth is an excellent method in treating patients with oligodontia. It provides benefits of dental support against prosthetic occlusal forces, protecting the alveolar bone around the teeth, and preserving the sense of proprioception at periodontal receptors [20].

Conclusion

A dentist may come across any case having multiple congenital missing teeth which may or may not be always associated with multiple other abnormalities as seen in syndromes. This case highlights non syndromic oligodontia which is a rare occurrence

as this entity exists with many syndromes. Such cases prompt dentist to see oligodontia as an isolated entity. Management of such patients requires integrated multidisciplinary approach. Thus, the cases should be evaluated carefully by clinicians and early diagnosis and treatment planning should be made for appropriate treatment modalities and to minimize the complication of these dental anomalies.

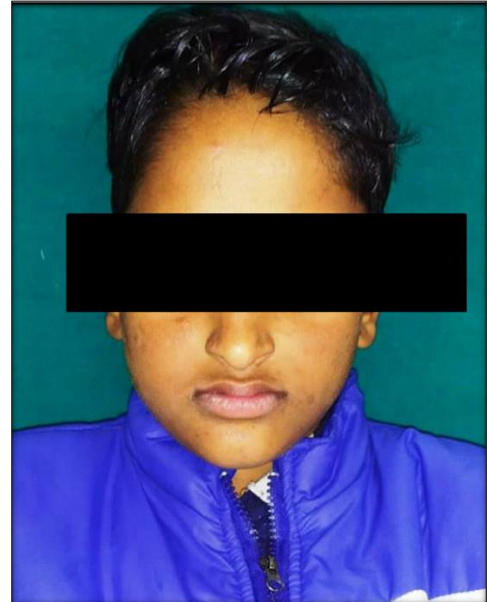

Fig 1: Facial Profile

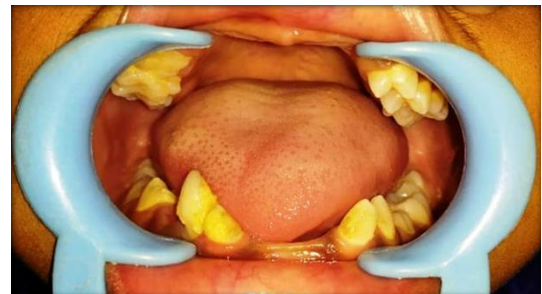


Fig 2: Clinical picture of oral cavity revealing multiple missing teeth

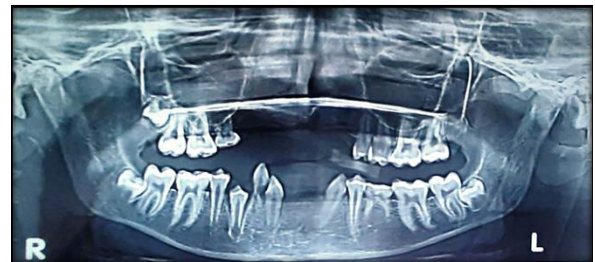

Fig 3: Panaoramic radiograph

References

1. Pinheiro M, Freire-Maia N. Ectodermal dysplasias: A clinical classification and a causal review. *Am J Med Genet.* 1994; 53:153-62.
2. De Coster PJ, Marks LA, Martens LC, Huysseune A. Dental agenesis: Genetic and clinical perspectives. *J Oral Pathol Med.* 2009; 38:1-17.

3. Durstberger G, Celar A, Watzek G. Implant-surgical and prosthetic rehabilitation of patients with multiple dental aplasia: A clinical report. *Int J Oral Maxillofac Implants*. 1999; 14:417-23.
4. Goya HA, Tanaka S, Maeda T, Akimoto Y. An orthopantomographic study of hypodontia in permanent teeth of Japanese pediatric patients. *J Oral Sci*. 2008; 50:143-50.
5. Dhanrajani PJ. Hypodontia: Etiology, clinical features, and management. *Quintessence Int*. 2002; 33:294-302.
6. Klein ML, Nieminen P, Lammi L, Niebuhr E, Kreiborg S. Novel mutation of the initiation codon of PAX9 causes oligodontia. *J Dent Res*. 2005; 84:43-7.
7. Créton MA, Cune MS, Verhoeven W, Meijer GJ. Patterns of missing teeth in a population of oligodontia patients. *Int J Prosthodont*. 2007; 20:409-13.
8. Sharma S, Bedi S. Dystrophic epidermolysis bullosa associated with non-syndromic hypodontia. *Indian Dermatol Online J*. 2013; 4:296-9.
9. Giray B, Akça K, Iplikçioglu H, Akça E. Two-year follow-up of a patient with oligodontia treated with implant- and tooth-supported fixed partial dentures: A case report. *Int J Oral Maxillofac Implants*. 2003; 18:905-11.
10. Bergendal B. Orodental manifestations in ectodermal dysplasia-a review. *Am J Med Genet A*. 2014; 164(10):2465-71.
11. Juuri E, Balic A. The Biology Underlying Abnormalities of Tooth Number in Humans. *J Dent Res*. 2017; 96(11):1248-1256.
12. Jepson NJ, Nohl FS, Carter NE, Gillgrass TJ, Meechan JG, Hobson RS, *et al*. The interdisciplinary management of hypodontia: Restorative dentistry. *Br Dent J*. 2003; 194:299-304.
13. Savasta S, Carlone G, Castagnoli R, *et al*. X-linked hypohidrotic ectodermal dysplasia: new features and a novel EDA gene mutation. *Cytogenet Genome Res*. 2017; 152(3):111-116.
14. Fournier BP, Bruneau MH, Toupenay S, Kerner S, Berdal A, Cormier-Daire V, Hadj-Rabia S, Coudert AE, de La Dure-Molla M. Patterns of Dental Agenesis Highlight the Nature of the Causative Mutated Genes. *J Dent Res*. 2018; 97(12):1306-1316.
15. Larmour CJ, Mossey PA, Thind BS, *et al*. Hypodontia – a retrospective review of prevalence and etiology. Part I. *Quintessence Int*. 2005; 36:263-70.
16. Mostowska A, Kobiela A, Trzeciak WH. Molecular basis of non-syndromic tooth agenesis: mutations of MSX1 and PAX9 reflect their role in patterning human dentition. *Eur J Oral Sci*. 2003; 111:365-70.
17. Mahadevi B, Puranik RS, Shrinivas S. Oligodontia: A case report and review of literature. *World J Dent*. 2011; 2:259-62.
18. Toolson LB, Smith DE. A 2-year longitudinal study of overdenture patients. Part I: Incidence and control of caries on overdenture abutments. *J Prosthet Dent*. 1978; 40:486-491.
19. Renner RP, Gomes BC, Shakun ML, *et al*. Four-year longitudinal study of the periodontal health status of overdenture patients. *J. Prosthet. Dent*. 1984; 51:593-598.
20. Cakur B, Dagistan S, Bilge M. Nonsyndromic oligodontia in permanent dentition: Three siblings. *Internet J Dent Sci*. 2006; 3:2.